

Calcaneus Fractures: A Review Article

John D. Maskill, MD^a, Donald R. Bohay, MD^{b,c,*},
John G. Anderson, MD^{b,c}

^a*Grand Rapids Medical Education and Research Center/Michigan State University Orthopaedic Surgery Residency Program, 300 Lafayette, Suite 3400, Grand Rapids, MI 49503, USA*

^b*Department of Orthopaedic Surgery, College of Human Medicine, Michigan State University, 1111 Leffingwell NE, Suite 100, Grand Rapids, MI 49525, USA*

^c*Orthopaedic Associates of Grand Rapids, P.C., Foot and Ankle Division, 1111 Leffingwell NE, Suite 100, Grand Rapids, MI 49525, USA*

Calcaneus fracture management has been a source of controversy for at least the last century. These fractures present many obstacles to the surgeon. The irregular bony anatomy, the complicated joint mechanics between the tarsal bones, and the delicate soft tissue envelope in which they sit have made these fractures a challenge. Many classification schemes, operative techniques, and postoperative regimens have been proposed, but a true consensus has not been reached. Despite significant advances in diagnostic and therapeutic tools, many topics of debate still arise. Definitive management has been slow to progress secondary to the lack of standardization in fracture classification and evaluation [1–5]. Experienced surgeons do acknowledge a significant learning curve [5,6], yet conservative management often times is wrought with functional impairment and disability [4–11].

Since the original description of these fractures, they have been recognized as being problematic. There has been one fact upon which all have been in agreement—the socioeconomic impact is large [4,12–15]. These fractures typically occur in the young and middle-aged male industrial worker and results in significant economic importance [4,15]. In 1916, Cotton and Henderson [16] stated, “ordinarily speaking, the man who breaks his heel bone is ‘done’ so far as his industrial future is concerned.” This impact propelled the orthopedic community to seek methods to obtain better outcomes.

* Corresponding author. Department of Orthopaedic Surgery, College of Human Medicine, Michigan State University, 1111 Leffingwell NE, Suite 100, Grand Rapids, MI 49525.

E-mail address: dbohay@oagr.com (D.R. Bohay).

History

In 1856, Malgaigne first drew out the complex anatomy of the calcaneus fracture in his atlas [3,12,15]. It was drawn with such precision as to compare favorably with biomechanical and clinical studies using CT more than a century later [6,17]. Initially Cotton and Wilson [18] and McLaughlin [19] believed that operative fixation was extraordinarily difficult and recommended closed reduction. This was done with a hammer to reduce the lateral wall in attempts to “reimpact” the fracture. This technique was given up and they went on to manage the malunions after the fractures had healed [18].

In 1931, Böhler [12] first described the pathomechanics behind the fracture. He advocated anatomic reduction by placing the foot over a “wooden wedge.” The foot was then plantarflexed, and skeletal traction was used to reduce the tuberosity. The talus was lifted off the calcaneus to restore the joint space between the two. The patient was placed in a plaster cast to hold the reduction. He used the tuber-joint angle (Böhler’s angle, Fig. 1) to aid in diagnosis and to assess postreduction films.

In 1934, Westhues, of Germany, came up with a technique for percutaneous pin placement into the posterior tuberosity for reduction [2]. He recommended holding the reduction with plaster immobilization. This idea was popularized later in the United States by Gissane [2].

In 1935, Conn [14] was unhappy with the results of closed reduction techniques and commented on the “serious disabling injuries in which the end results continue to be incredibly bad.” He noted the traumatic flatfoot deformity which consisted of “pronated heels, planus arches, and valgus forefoot with pain.” His approach was to take the healed, malunited fracture and by performing a triple arthrodesis, restored position and alignment. He reported excellent results. A decade later, in 1943, Gallie [20] recommended only a subtalar arthrodesis for fractures that had healed.

Palmer [21] was unimpressed with closed and delayed treatment of these fractures. In his work published in 1948, he proposed performing an open

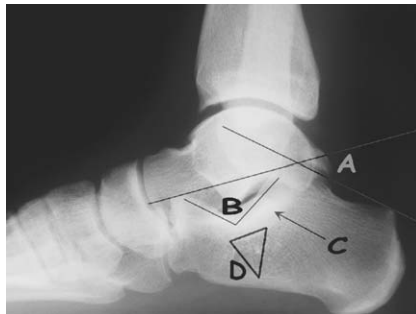


Fig. 1. (A) Böhler’s angle. (B) Angle of Gissane. (C) Thalamic portion of the calcaneus. (D) The “neutral triangle.”

reduction of the joint surface supplemented with bone graft through the use of a standard Kocher approach for acute calcaneus fractures. All of the patients were back to their previous work 4 to 8 months later; 90% reported excellent results. Essex-Lopresti [2] described similar findings. He determined that displaced articular fragments were joint depression fragments or tongue-type fragments. He continued with the use of Westhues and Gissane's method of percutaneous reduction for the tongue-type fragments, but recommended open reduction for the joint depression types using Palmer's approach. In this patient group, 91% returned to work in less than 1 year.

Unfortunately, not many could duplicate the results of Palmer. Thus, in the middle of the twentieth century, high infection rates and inadequate fixation predominated in the treatment of acute calcaneus fractures. Surgeons moved from open reduction to double and triple arthrodeses as advocated by Conn [14] and Gallie [20]. Lindsay and Dewar [22] compared nonoperative and operative results in 1958 and showed superior results in those who were treated nonoperatively. This article placed suspicion on the operative treatment of calcaneus fractures once again. The result was a trend in the 1960s and 1970s that favored non-operative management [3,6,19,23].

With the advent of CT scanning, Arbeitsgemeinschaft für Osteosynthesefür- gen (AO) principles of internal fixation, and introduction of antibiotics, surgeons have been able to obtain better outcomes with operative intervention [5,6,13, 24–26]. Open reduction with internal fixation (ORIF) is the preferred method of management for displaced intra-articular fractures of the calcaneus. Although methods continue to improve, the treatment is challenging and complications are frequent.

Anatomy

Understanding the anatomy of these fractures is a prerequisite to understanding the operative management. The calcaneus is the largest bone of the foot, and makes up the essential posterior portion of the longitudinal arch of the foot and lateral column. The bony architecture of the calcaneus is that of an irregularly shaped rectangle with four facets, three superiorly and one anteriorly. The largest facet, posteriorly, is oval, convex, and runs distal and slightly lateral at 45° in the sagittal plane [27]. It is separated from the other two facets by the calcaneal sulcus, which forms the inferior border of the tarsal canal medially and the sinus tarsi laterally. The sinus tarsi houses the interosseous ligament complex between the talus and calcaneus. The middle facet is concave and the anterior facet is flat. The middle and anterior facets are fused together in approximately 20% of cases [28]. The anterior process provides a biconcave joint surface to articulate with the cuboid. It functions as a saddle-type joint, and is part of Chopart's midtarsal joint. This structure acts as a solid buttress to the lateral column of the foot [27].

Medially, the sustentaculum tali emerges from the medial wall and is the most stable portion of the calcaneus. It is connected firmly to the talus by strong

talocalcaneal ligaments. The flexor hallucis longus tendon courses inferior to it, and produces a dynamic compressive-type force. All of these structures help to hold the sustentaculum firmly in position relative to the talus when a fracture occurs. Laterally, the cortical wall is thin. The peroneal tubercle sits approximately 2 cm to 3 cm inferior to the lateral malleolus. The peroneal tendons are guided by grooves under this tubercle and by the retinaculum. Posteriorly, the inferior two thirds of the calcaneal tuberosity provide the Achilles tendon an insertion point [27].

The internal architecture of the calcaneus is characterized by longitudinal trabeculae that merge with transverse trabeculae to form a strong support under the posterior and anterior articular facets [29]. This mass of bone was termed the thalamic portion (see Fig. 1) by Soeur and Remy [30] in the 1970s. Along the neck of the calcaneus a thick cortical layer of bone forms the “crucial angle of Gissane” with a normal value of 120° to 145°. Underneath this portion lies the neutral triangle [31], which is an area, that in some patients, is virtually void of bone (40%) or consists of sparse trabeculae (60%). This “neutral triangle” lies directly underneath the lateral process of the talus. This chamber can extend medially and anteriorly. It is into this chamber that the primary fracture line occurs [29].

Mechanism of injury

Intra-articular fractures of the calcaneus frequently occur secondary to an applied axial load [2,12,14,17]. Most often, this is from a high-energy trauma, such as a fall from a height or motor vehicle accident where most of the force is dissipated through the heel. Men are four to five times more likely to sustain this type of injury [4,15]. The position of the foot, the amount of force applied, and the quality of the bone determine the fracture pattern [32].

The calcaneus is positioned eccentrically underneath the talus in a slightly valgus position. As the talus undergoes compression, the lateral process forces the subtalar joint into eversion and acts as a wedge at the angle of Gissane [2,12,32]. This produces the primary fracture line that was described by Essex-Lopresti [2]. Two main fragments are produced by this fracture line—the posterolateral fragment that contains the tuberosity and body, and the superomedial fragment that contains the sustentaculum. The fracture line runs superolateral to inferomedial. The fracture line extends into the calcaneocuboid joint or into the anterior facet as the force of injury increases. As the calcaneus is positioned in more valgus, the fracture line begins further laterally, whereas if the calcaneus is in a more varus position the fracture line is medialized [32,33].

As the force of the compressing talus continues, a secondary fracture line can be formed beginning at the posterior aspect of the subtalar joint. Essex-Lopresti [2] believed that there were two types of fracture fragments that occurred with this secondary fracture line, depending on the direction in which the force was dissipated (Fig. 2). The joint depressed fragments had a secondary fracture line

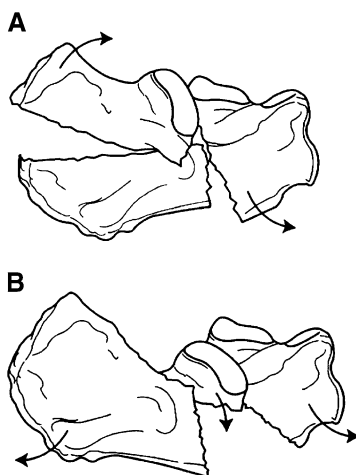


Fig. 2. (A) Lateral drawing of the classic Essex-Lopresti tongue-type fracture. The fracture line extends directly posterior to produce a large tongue-like fragment through the tuberosity. (B) Lateral drawing of the classic Essex-Lopresti joint depression-type fracture. The fracture line only extends just beyond the posterior facet. This piece is free to depress down into the "neutral triangle" zone. (From Fitzgibbons TC. Fractures and dislocations of the calcaneus. In: Buchholz RW, Heckman JD, editors. Fractures in adults. 5th edition. Philadelphia: JB Lippincott Company; p. 2152; with permission).

posterior and superior to the posterior facet. The fracture line ran downward only, essentially not involving the tuberosity. This created a free superolateral fragment that was displaced inferiorly into the cancellous deficient neutral triangle. The tongue-type fragment, however, showed a secondary fracture line that extended longitudinally into the tuberosity. The anterior portion of the fragment was depressed down into the neutral triangle with the posterior portion elevated, which essentially reversed Böhler's angle.

These observations have been validated by other studies in which calcaneus fractures were created [17,34]. The primary and secondary fracture lines were seen consistently (Fig. 3). One portion of the primary fracture line divided the calcaneus into medial and lateral halves. The other divided it into anterior and posterior halves. Depending on the amount of force and the position of the foot, the primary fracture line extended anteriorly and creating an anterolateral fragment. Multiple joint-depressed and tongue-type fragments were noted.

Radiographic assessment

When a patient is evaluated initially, plain radiographs always should be done. If a intra-articular fracture is identified, a CT scan should be obtained. For the calcaneus, many different radiographs have been described and can be difficult to interpret consistently [4]. The CT scan of the calcaneus has brought new di-

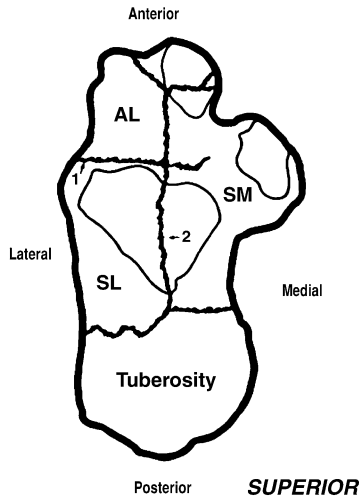


Fig. 3. 1, Primary fracture line dividing in the coronal plane; 2, primary fracture line dividing longitudinally in the sagittal plane. Superomedial (SM) fragment contains the sustentaculum; the lateral fragment contains the tuberosity. In the joint depression-type fracture, a superolateral (SL) fragment is created. With more energy, the anterolateral (AL) fragment is created. (From Carr JB. Mechanism and pathoanatomy of the intra-articular calcaneal fracture. Clin Orthop 1993;290:37; with permission.)

agnostic and prognostic ability to the operating surgeon [1,5,6,17]. Because of the association of calcaneus fractures with injuries of the spine, radiographs of the lumbar spine should be considered if clinically appropriate.

The plain radiograph series that should be obtained includes a lateral radiograph of the hindfoot, an anteroposterior (AP) radiograph of the foot, and a Harris axial radiograph of the heel (Fig. 4) [35]. The lateral radiograph of the hindfoot (see Fig. 1) allows evaluation of the height of the calcaneus, Böhler's angle, and the angle of Gissane. Small avulsion fractures off the anterior process or posterior tuberosity also can be seen on this view. The diagnosis of a calcaneus fracture should be confirmed on this view. Böhler's angle [12] usually is depressed and the angle of Gissane [36] is widened. The angle of Gissane only increases when the posterior facet is separated from the superomedial fragment. If only the lateral half of the facet is fractured and depressed, a "double density" sign is noted. In this case, Böhler's angle also will be normal [35]. The depressed articular surface usually is rotated 90° relative to the remainder of the joint surface. The lateral radiograph also indicates whether the fracture is a joint-depressed-type or a tongue-type [2]. The AP radiograph of the foot shows possible extension of the fracture line into the calcaneocuboid joint and any associated midfoot pathology. The Harris axial radiograph is useful to look at the lateral wall comminution and position of the heel. Only the central portion of the posterior articular facet is able to be visualized. The rest of the joint is superimposed with other structures and cannot be relied on to evaluate the articular surface in its

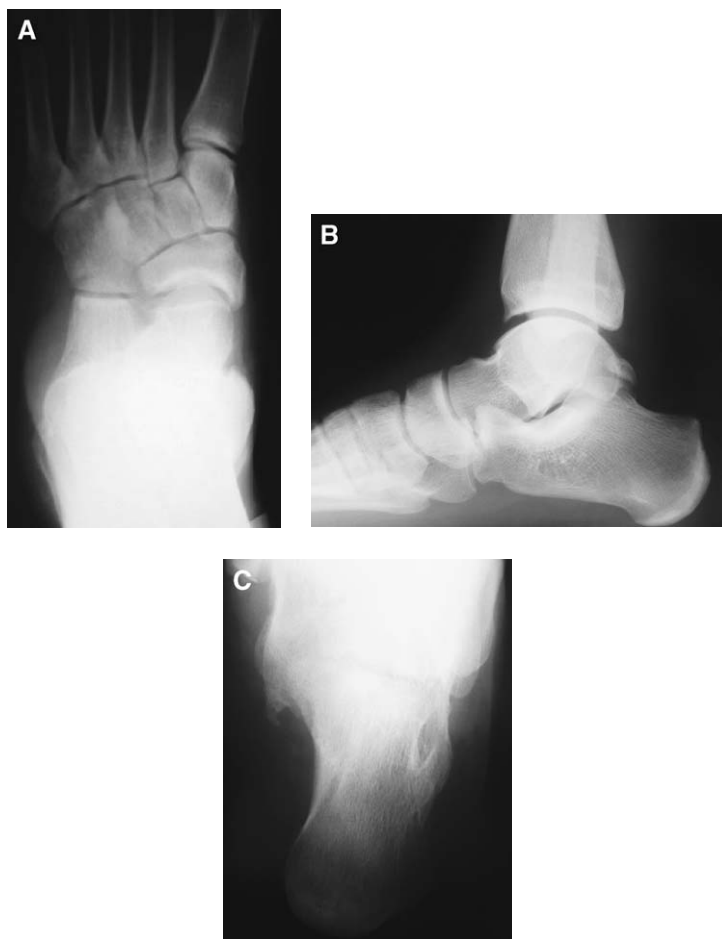

Fig. 4. Normal roentograms. (A) AP view. (B) Hindfoot lateral view. (C) Harris axial heel view.

entirety [27]. This view is difficult to get in the acute setting secondary to pain. Brodén's projection I (Fig. 5) [37] is an excellent way to visualize the entire joint surface [4,5,35]. This view is obtained by laying the patient supine with the radiograph cassette under the leg and ankle. The foot is in neutral flexion, and the leg is rotated internally 30° to 40° . The x-ray beam is centered over the lateral malleolus and four radiographs are taken with the tube angled at 40° , 30° , 20° , and 10° . This shows the articular surface of the posterior facet from anterior to posterior and is most helpful in the operating room when evaluating joint reduction.

With the advent of CT scanning, our understanding of these fractures has increased significantly [5,6,33,38]. Coronal and transverse images are obtained using 2-mm sections (Fig. 6). The coronal views are to be perpendicular to the

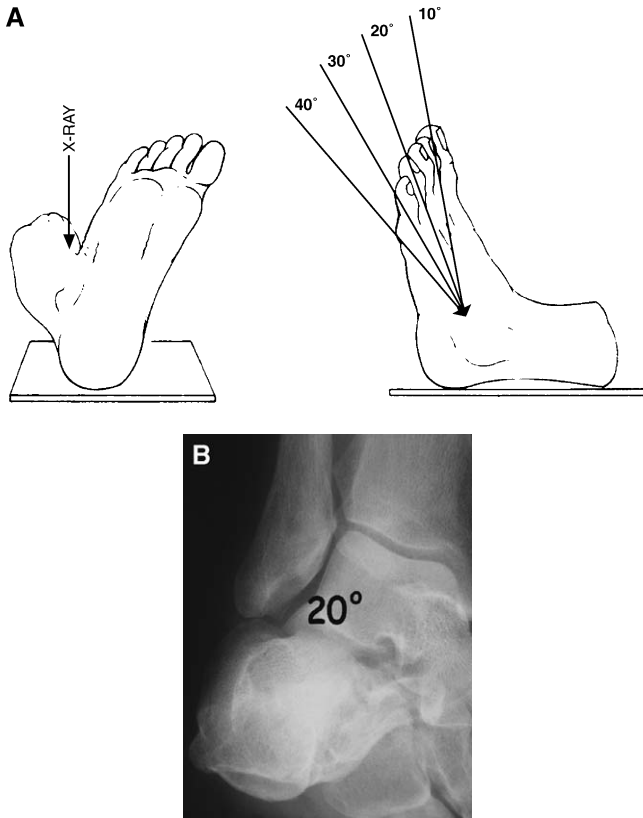


Fig. 5. Brodén's projection I. (A) Diagram depicting proper positioning with the x-ray beam. (B) A Brodén's view at 20° showing the posterior articular facet. (From Sanders R, Fortin P, DiPasquale T, et al. Operative treatment in 120 displaced intraarticular calcaneus fractures. Clin Orthop 1993;290:89; with permission.)

posterior articular facet, whereas the transverse views are parallel to the foot. All cuts are to be at least 2 mm in thickness to evaluate the calcaneus properly. The coronal views show the number and location of the articular fragments. Sanders et al [6] showed this to be of prognostic significance and is the basis of his classification scheme. The calcaneal body can be evaluated for widening and shortening, and the tuberosity for positioning (varus, valgus). The peroneal tendons can be identified and impingement can be evaluated. The transverse images also show the lateral wall blowout, because it shows comminution of the sustentaculum and calcaneocuboid joint surface. The anteroinferior posterior articular facet also is seen best on these cuts. Three-dimensional CT scanning has been studied over the past decade—and although the technology is improving—the cost-benefit ratio is high. In a recent study, it was recommended that surgeons who are not completely familiar with the three-dimensional anatomy of the

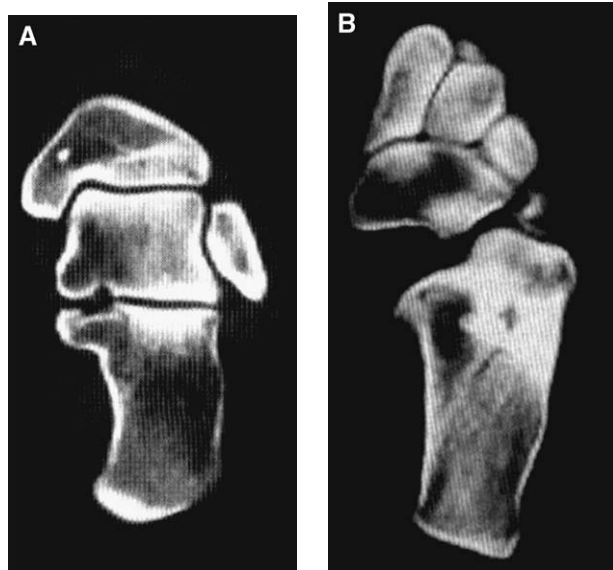


Fig. 6. (A) A coronal CT slice showing the posterior articular facet and varus or valgus alignment of the heel. (B) An axial CT slice depicting the calcaneocuboid joint and lateral wall of the calcaneus.

calcaneus could benefit from three-dimensional CT scans to assess the fractured articular surfaces better [39].

Classification

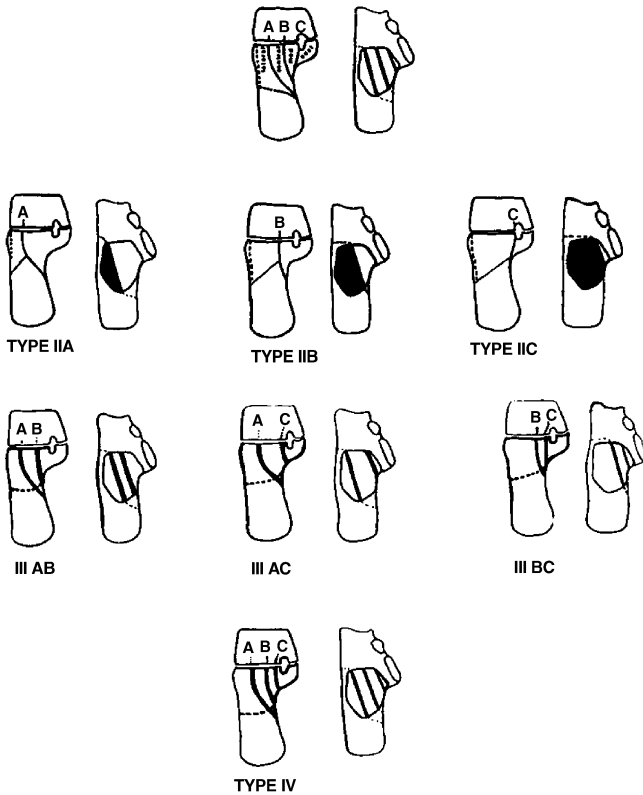
The inability to come to a consensus on the management of calcaneus fractures largely has been the result of the surgeon's inability to classify these fractures consistently [4,6]. Many classification schemes have been proposed throughout the last century [1,2,5,6,12,14]; however, most of them were based on standard plain radiographs which are difficult to interpret consistently. The result was different treatment options being used for the same fracture patterns with varying successes.

Böhler was one of the first to describe a classification system for calcaneus fractures [2]. In his system there were eight fracture types, four intra-articular types and four extra-articular fracture types [15]. There was no correlation between fracture type and outcome. Palmer [21] noted two different fracture types in his study, which Essex-Lopresti [2] later developed and popularized. The classification system was based on mechanism and described the tongue-type and joint depression-type of fragment (see Fig. 2). The difference between the two fracture types was the location of the secondary fracture line. The tongue-type fragment was described as having the posterior tuberosity attached to it, whereas the joint-depressed fragment did not. The fracture type determined the

treatment, but not the prognosis. These terms are still used to describe the fracture morphology.

In the 1970s, Soeur and Remy [30] came up with a classification system which was based on the number of articular fracture fragments. Plain radiographs (lateral hindfoot, AP, Harris axial view) were used to assess the posterior articular facet. First degree fractures were nondisplaced. Second degree fractures showed secondary fracture lines that resulted in three fragments. Third degree fractures were severely comminuted fractures and were unable to be classified. There was no mention as to whether the comminution was of the calcaneal body or of the articular facet. Their work did not correlate results with outcomes, but served as a stepping stone for modern classification systems.

The precise assessment of fracture fragments by CT scan provides a considerable advantage for modern classification schemes [1,5,6,38]. The most



Sanders Classification

Fig. 7. Sanders classification. A through C are the various types of primary fracture lines that one can see, depending on the position of the heel at the time of injury. (From Sanders R, Fortin P, DiPasquale T, et al. Operative treatment in 120 displaced intraarticular calcaneus fractures. Clin Orthop 1993;290:89; with permission.)

widely used classification system is that of Sanders et al (Fig. 7) [6]. This system bases its classification on the number of fracture fragments that is identified on a semicoronal CT image. The image used is the one that displays the widest undersurface of the posterior facet of the talus. Sanders et al described the talus as being divided into three columns by two lines. These lines divided the posterior articular facet into three potential pieces: a medial, a central, and a lateral fragment. The addition of a third line that is located just medial to the medial edge makes for a fourth possible fracture piece, the sustentaculum portion. All non-displaced fractures (regardless of the number of fracture lines) are classified as type I; one fracture line is a type II; two fracture lines is a type III; and three or more fracture lines is a type IV. The lines are lettered according to placement on the facet. Lateral fracture lines are type A, central lines are type B, and medial lines are type C. This system has been useful in terms of determining treatment, and was shown to correlate well with prognosis and level of operative difficulty.

Clinical evaluation

Clinical evaluation of a fractured hindfoot is critical. Because the soft tissue envelope is fragile, treatment must be performed accordingly. The displacement of the fracture and the degree of soft tissue injury are directly proportional to the amount of force that is seen at the time of injury [2,4,15,17]. In severe cases, an open fracture may occur. In subtle cases, the medial spike of the superomedial fragment breaks the skin barrier with evidence of a small medial puncture wound. A high index of suspicion is needed to avoid neglecting this dangerous fracture. The surgeon must be careful not to overlook other fractures that might have occurred in the foot. One also must be cognizant of the correlation of lumbar spine fractures with this injury [40]. A thorough neurologic examination should be performed.

Typical features of calcaneus fractures are significant swelling and hematoma formation within the hindfoot. Frequently, the patient is unable to bear weight on that extremity. Often, the foot has hindfoot bulging from the lateral wall blowout. The peroneal tendons should be palpated along the posterior aspect of the lateral malleolus to be sure that they have not dislocated. If the patient is seen after 6 hours, the swelling usually is so severe that the skin creases have disappeared. Swelling may be so severe that blisters form—intradermal (clear fluid) and full thickness (serosanguinous fluid) types [41,42]. Some fracture fragments might be tenting the skin with the eminent risk of full-thickness skin necrosis [2,15].

Pain often is severe and compartment syndrome always should be ruled out. Compartment syndrome is noted often in high-energy injuries or crush-type injuries. Manoli and Weber [43] described nine compartments in the foot. Three compartments run the entire length of the foot, whereas six are confined to the forefoot or the hindfoot. The four interosseous compartments and the adductor compartment make up the forefoot compartments and the calcaneal compartment

lies in the hindfoot. The calcaneal compartment contains the quadratus plantae and the lateral plantar nerve. This compartment is the one that is affected most commonly in this type of fracture. The calcaneus—an extremely vascular bone—bleeds into the compartment and affects the pulse pressure to the point where arterial flow is compromised. If compartment syndrome is believed to be a possibility, the pressures should be measured. Because there is no current literature to prove that the foot can withstand greater pressures than other fascial compartments in the body, the current recommendation is to perform fasciotomies with pressures greater than 30 mm Hg, or within 10 mm Hg to 30 mm Hg of the diastolic blood pressure. These pressures have been found to occur in 10% of calcaneus fractures [44]. If the diagnosis is missed, the patient can go on to develop intrinsic contractures, claw toe deformities of the lesser toes, sensory abnormalities, stiffness, chronic aching, and atrophy with weakness [43,44].

Options for treatment

Treatment options can be broken down into the following categories: emergent, nonoperative, minimally invasive ORIF, standard open reduction with internal fixation, and primary arthrodesis.

Emergency procedures

Emergent procedures are performed only in cases in which the soft tissue envelope is compromised. Situations in which this might occur are a foot that develops compartment syndrome, an open fracture, or severe tenting of the skin by displaced bony fragments.

Compartment syndrome that has been confirmed with elevated pressures that are greater than 30 mm Hg or within 10 mm Hg to 30 mm Hg of the diastolic pressure should be dealt with emergently by performing a fasciotomy [43,44]. To do this, a medial incision that starts 4 cm anterior to the posterior heel and 3 cm superior to the plantar surface of the foot is made. Typically, the incision is approximately 6 cm in length. The medial compartment is opened and the abductor hallucis muscle is elevated until the medial intermuscular septum is seen (Fig. 8). This fascia is opened to release the deep calcaneal compartment. The lateral plantar nerve is at risk with this procedure because it lies just lateral to the medial septum. The dorsal compartments may be released as needed clinically, depending on the type of injury seen.

Open calcaneus fractures are much less common than closed fractures. Standard irrigation and debridement of the opened areas should be performed [4,15]. Most often, this is a small puncture wound medially from the spike of the superomedial fragment. The wound is covered with a standard dressing or a

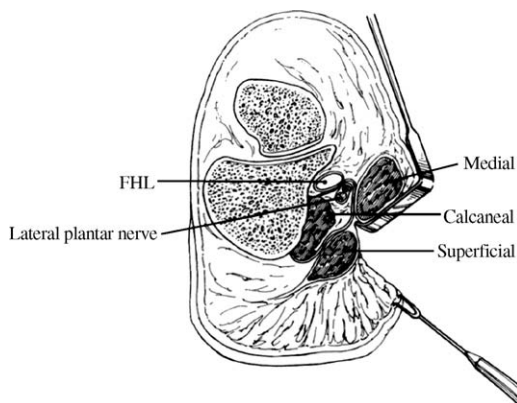


Fig. 8. Medial fascial release of the foot. FHL, flexor hallucis longus. (From Myerson M, Manoli A. Compartment syndrome of the foot after calcaneus fractures. *Clin Orthop* 1993;290:146; with permission.)

vacuum-type dressing. An external fixator [15,45] can be applied as tibiometatarsal transfixation; alternatively, a three-point distractor can be placed, with pins in the talus, the calcaneal tuberosity, and the cuboid. The wound is debrided again in 48 hours to 72 hours and appropriate closure is decided. Internal fixation can be delayed up to 3 weeks to allow for the soft tissues to stabilize [6,15,45,46]. In cases where inadequate coverage for closure is noted, a free flap procedure can be considered [47].

Severely displaced bony fragments which tent the skin can cause full thickness necrosis. When performing the initial assessment of the foot, the surgeon must look for these areas. Full thickness skin necrosis can occur quickly and become a significant treatment hurdle. These fragments should be reduced with a percutaneous reduction technique with K-wires to allow the soft tissues to stabilize before a formal open reduction is performed [2,5,45,48].

Nonoperative management

The question must be asked, “What fractures should be reduced, and what fractures can be treated nonoperatively?”. This question has generated significant debate in the literature [13,49,50]. Most surgeons agree that fractures that are nondisplaced can be treated nonoperatively, and those that show significant displacement of the articular surface should be reduced. What is the definition of significant? Sanders et al [6] defined near anatomic reduction as approximately 3 mm of incongruity [6]. Zwipp and colleagues, however, perform an open reduction with approximately 1 mm step off [5,51–53]. It was shown that 1 mm to 2 mm of articular incongruity in the posterior facet is responsible for a large contact load shift. This was based on cadaveric studies using pressure film [54,55]. Taking this into consideration, patients who have fractures that are

nondisplaced or have less than 2 mm of displacement could be treated nonoperatively [4,5,13,25,49,56]. Patients who have diabetes mellitus (DM), peripheral vascular disease, or traumatic injury are not candidates for surgery. If the soft tissue envelope is believed to be questionable in any way (eg, those who have significant blistering or massive edema), the window of operative opportunity may pass [4,5,15].

Nonoperative treatment typically includes rest, ice, elevation, and a posterior splint until the swelling decreases. A compression dressing or stocking is helpful with swelling. Early motion is started immediately. After the swelling is down, the patient can be fitted with a removable boot or splint fixed at 90° to prevent an equinus contracture [4]. Weight-bearing status is controversial. Zwipp et al [5] restrict the patient immediately to a 20-kg limit on the affected extremity for 6 weeks to 10 weeks. Conversely, Sanders et al [4] recommend a nonweight-bearing status for 12 weeks. Many investigators' recommendations are in between these two [24,26,57–63].

Most investigators do not recommend formal reduction of these intra-articular fractures [4,13,25,50]; however, Omoto and Nakamura [64] describe a technique of repetitive squeezing combined with strong longitudinal traction while the patient is anesthetized. The patient is then placed in a short-leg walking cast with the heel in 45° of equinus. This method relies on ligamentotaxis. They reported good to excellent results in 89 of 102 fractures; patients who had severe tongue-types and comminuted joint depressed-types could not be reduced successfully. The criteria for adequate reduction were not given, nor were the fractures classified by CT.

The malunion that can follow nonoperative treatment can result in significant clinical problems [4,9,11,15,65–67]. A reduction of the articular surface never is obtained and carries the risk of arthritis in the subtalar joint, the calcaneocuboid joint, and even the tibiotalar joint with chronic dorsiflexion of the talus [4]. The patient could develop problems with shoe wear because the heel often is wide, short, and in a varus position. The peroneal tendons can be a source of pain secondary to impingement or chronic dislocation as a result of the lateral wall blowout.

Minimally invasive options

Minimally invasive techniques are attractive in the management of intra-articular calcaneus fractures. The benefit of such techniques are less soft tissue trauma, and possibly, reduced cost. The risk involved, however, is the possible acceptance of an incongruent reduction from lack of visualization. Indirect closed reduction with percutaneous fixation has been done since Westhues introduced the idea in 1934 [2,15]. Gissane popularized this method in the United States during the next decade [2]. Essex-Lopresti [2] reported using this technique to reduce tongue-type fracture fragments. He mentioned that joint depressed fragments had to be opened because adequate control of the depressed frag-

ment was unable to be obtained. These investigators used plaster to immobilize their reductions.

Today, this type of technique is useful to some investigators. Tornetta [48] described the use of this technique; instead of Steinmann pins he used percutaneous screws. Rammelt et al [51] have used this type of reduction and fixation with Sanders type IIC fractures. This fracture fragment is essentially the entire posterior facet because the fracture line is far medial. Therefore, the surgeon can reduce the joint by facilitating reduction of the fracture fragment. In a recent article, however, Rammelt et al [51] mentioned the idea of using a 1.9-mm/0° arthroscope to view the reduction. This allows the indications for percutaneous reduction to be advanced to Sanders types IIA and IIB fractures. If one could visualize the joint surface and the reduction there would be no need to open. Zwipp attempted percutaneous operative fixation on 21 Sanders types IIA and IIB intra-articular fractures [52]. Three were unable to be reduced by way of percutaneous method and thus, were discarded. The remaining 18 were able to be reduced anatomically because they were visualized arthroscopically. Time to operation was an average of 6 days postinjury to allow for stabilization of the soft tissues. The patients were placed in a lateral decubitus position on the noninjured side. Subtalar arthroscopy was performed first by way of the anterior or posterolateral portal, depending on the fracture location. Any small bony avulsions or cartilaginous bodies were removed through a second portal (posterolateral or anterior). Reduction of the tuberosity was undertaken with a percutaneously placed Steinmann pin as in open reduction with internal fixation (ORIF). The impacted fragment was loosened with varus/valgus stress and the pin pulled downward to restore the height. Percutaneous screws were placed into the tuberosity and into the superomedial fragment. This was controlled by way of fluoroscopy. K-wires were placed to assist in manipulation of the depressed fragment if needed. If impacted, a pestle was inserted percutaneously to tap the joint surface back to position. After the reduction was visualized arthroscopically and found to be adequate, percutaneous screws were placed into the thalamus of the calcaneus parallel to the posterior facet. Anterior process fractures also were fixed percutaneously unless there was significant comminution. Patients were treated with physical therapy starting on postoperative day 1 with active range of motion exercises.

One year postoperatively, 15 patients were available for review. Subjectively, all were satisfied and the average American Orthopaedic Foot and Ankle Society (AOFAS) Ankle/Hindfoot Score was 94.1. Twelve patients experienced no pain during activities of daily living and work, whereas 3 reported occasional pain. Return to work was noted at an average of 10.9 weeks. No wound complications were seen (wound sloughs, deep infection, or hematoma). Bohler's angle was improved from a mean of 13.1° to a mean of 25.8° postoperatively. It was concluded that Sanders type II fractures could undergo a percutaneous closed reduction; IIA and IIB types require arthroscopic assistance. In skilled hands, this could minimize scar formation, and thus, stiffness, and decrease the incidence of wound problems. This cohort could not be compared with the cohort that underwent ORIF because of the incorporation of more complex fracture patterns [15].

Open reduction internal fixation

If a surgeon elects to perform an ORIF, the timing is critical. Massive swelling is a contraindication to surgery on a closed fracture [65,68]. Time must be allotted for this to recede. Sanders [4] recommended looking for a positive wrinkle test (Fig. 9). This test is performed by direct palpation of the skin over the lateral aspect of the calcaneus and by visual evaluation of this area when the patient dorsiflexes and everts the foot. If skin wrinkling is seen and no pitting edema is present, the patient is said to have a positive test and the operation may be performed. Some studies showed good results with the use of foot pumps or compression stockings to eliminate edema [69,70]. Generally, if longer than 3 weeks has elapsed since the time of injury, nonoperative intervention is the best option because the fragments most likely have started to consolidate [4,13,15,25].

After the operative timing has been determined, the approach to the fracture needs to be addressed. Several approaches have been advocated throughout the years. These include the medial [33,57], sustentacular [15], sinus tarsi [71], and extended lateral approaches [4,5,24,46,59,63]. As operative intervention became popular again in the mid- 1970s, investigators focused more on the restoration of the shape of the calcaneus rather than on the posterior facet. This led McReynolds and Burdeaux to use the medial approach so as to obtain a solid reduction of the tuberosity to the superomedial fragment [33,57]. The posterior facet was reduced through the fracture under fluoroscopic guidance. There was no direct visualization of the facet from this approach. This led to inadequate reduction of the joint surface. In his 21-year review, Burdeaux [57] reported the need for a lateral incision to assist in reduction of the posterior facet in 14 of 63 fractures. Stephenson [62,72] then reported on the combined (medial and lateral) approach, for which he advocated going medially only if the tuberosity was unable to be reduced adequately. A sustentacular approach was mentioned in the literature for obtaining reduction of isolated sustentaculum fractures [15]. A 3-cm to 5-cm incision is made directly over the palpable sustentaculum (2 cm below and 1 cm distal to the medial malleolus). After reduction of the medial facet, 3.5-mm

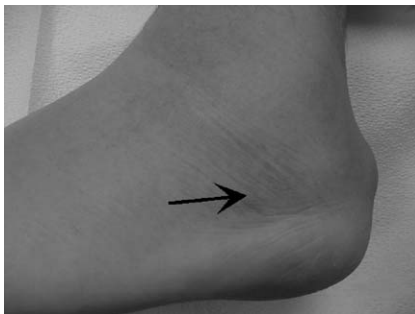

Fig. 9. A positive wrinkle test. Wrinkles occur when the swelling has gone down indicating that it is safe to proceed with ORIF.

screws can be placed aiming slightly plantar so as to avoid the sinus tarsi and the posterior facet.

Currently, most investigators prefer the “extended lateral approach” with the “no-touch” technique for displaced intra-articular fractures of the posterior facet [4,5,24,46,59,63]. The advantages are in obtaining an excellent view of the posterior facet and lateral wall of the calcaneus. The original lateral, or Kocher, approach initially was popularized by Palmer [21] in the 1940s, but results were not able to be duplicated. Wound sloughs and a high infection rate were frequent, owing to the fragile soft tissue envelope laterally and the watershed area in this region. Letournel [59] modified Palmer’s approach by placing the incisions more posteriorly and inferiorly using a full thickness skin flap so as not to disrupt the peroneal tendons, sural nerve, or calcaneofibular ligament. This approach has been used successfully in several large studies [1,4,5,13,24,26,46,50,59,60,63].

The patient is placed in a lateral decubitus position with the affected side up. This approach uses an L-shaped incision following the shape of the foot (Fig. 10). The incision is directed more posteriorly toward the anterolateral border of the Achilles tendon, making a right angle as the plantar surface of the foot is approached. This approach is then developed as a full-thickness flap, staying subperiosteally, by elevating the peroneal tendons, sural nerve, and the calcaneofibular ligament. The “no-touch” technique is brought into play as K-wires are placed into the lateral malleolus and the talar neck and bent to function as retractors. This preserves the fragile blood supply to the flap which can be compromised by overretraction or excessive handling. After the flap is established properly, an excellent view of the posterior facet and the lateral wall of the calcaneus is possible [4,15,59,73,74].

The lateral wall is elevated and hinged inferiorly so as to obtain access to the depressed posterior articular fragment. The primary fracture line can be seen. Often, the depressed joint surface is rotated 90°. This superolateral fragment is rotated out of the calcaneal body and decompresses the remaining fracture. After this is done, the tuberosity is reduced to the sustentacular, or superomedial, fragment. This can be performed by placing a Steinmann pin into the tuberosity for leverage [2,15], or by placing a periosteal elevator [4] into the fracture site and

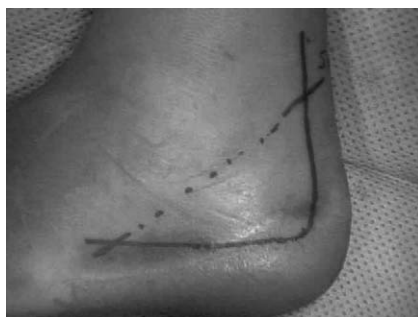

Fig. 10. Extended lateral approach incision. Dotted line refers to the course of the sural nerve.

levering the tuberosity down while shifting it medially. This restores the height and length of the calcaneus and brings the heel out of varus.

After the height and length have been restored, attention can be focused on the joint reduction. The joint is reduced from medial to lateral, using the superomedial fragment as the stable piece [4,15,75]. The anterolateral corner of the superolateral fragment should line up with the posterolateral corner of the anterolateral fragment to restore Gissane's angle properly [4]. After the articular surface is reapproximated, 3.5-mm cortical screws are placed from lateral to medial into the sustentacular bone. Brodén's views are an excellent way to assess the reduction of the posterior facet using intraoperative fluoroscopy [4,15,35]. After the joint surface is reduced, the body of the calcaneus is ready for fixation. At this point, there is most likely a large defect from the impaction of the cancellous

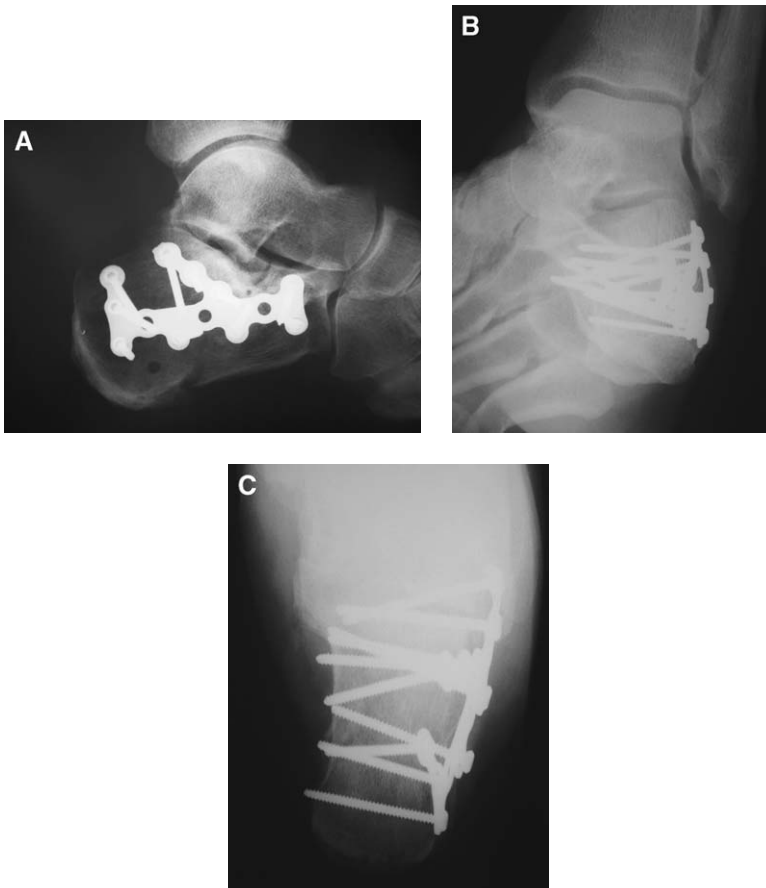


Fig. 11. (A) A lateral radiograph of a calcaneus that was reduced in a standard open fashion using the extended lateral approach. (B) A Brodén view of the posterior facet to show congruency. This view also can be obtained intraoperatively. (C) A Harris axial heel view showing adequate placement of hardware.

bone by the depressed articular fragment. Whether to graft bone is another controversial topic. It was shown in numerous studies that bone graft is not needed here, and this “neutral triangle” will fill in with cancellous bone within 8 weeks [4,25,62,63,76,77]. Other investigators advocate its use for unstable reductions [6,21,26,60]. The lateral wall is laid back over the calcaneus and an anatomically shaped plate is fixed into position. If there is comminution of the anterior process and into the calcaneocuboid joint, this can be fixed with screws that are placed in a lag fashion. If, however, the comminution is too great for adequate purchase, the calcaneocuboid joint can be spanned with a plate.

The use of several kinds of plates have been advocated through the years, such as a 3.5-mm reconstruction plate [26,78], an “H-shaped plate” [26], a “Y-shaped plate” [59], a “T-shaped plate” [58], a “perimeter plate” with an oblique strut [4,63], a locking plate [15], and a combination of these. The proper plate has a low profile, allows screws directly underneath the joint surface, and spans the body of the calcaneus to provide three-point fixation. The anatomically shaped plates allow the most convenient options for screw placement. These plates provide adequate support for the joint, tuberosity, thalamic portion of the body, and the anterior process (Fig. 11).

Primary subtalar arthrodesis

In Sanders type IV fractures, an anatomic reduction of the articular surface may not be able to be obtained. In Sanders et al’s [6] own study of 120 calcaneus fractures, of the 11 feet that had a type IV fracture, none had an anatomic reduction and only 3 had a “near” anatomic reduction. Only one of these feet had a good outcome. Because of the inability to reduce the joint, some investigators recommend a primary subtalar joint arthrodesis. Before this can be done, the calcaneal body height and length should be restored in a manner similar to that described previously. The joint surface also should be reduced as best as possible. After this is done, the remaining cartilage can be removed from both surfaces of the posterior facet, and bone graft can be used to assist with the arthrodesis. Typically, lag screws are placed from the tuberosity into the talus in addition to the lateral plate for the body of the calcaneus.

Buch et al [79] performed a study of 12 patients who were treated in this manner for severely comminuted intra-articular fractures. Eleven of these patients had returned to their original occupation within 9 months. The average AOFAS score was 72.4 postoperatively.

Postoperative care

According to the literature, the overall consensus is to start early postoperative motion. Zwipp and colleagues [5,15,51–53] recommend starting on postoperative day 1, whereas other investigators wait until the postoperative splint is removed

[6,25,26,46,59,63]. Weight bearing also is controversial. Some investigators start patients off immediately with partial weight bearing in their own shoes [5,16]. Sanders [4] recommends a boot fixed in neutral flexion so as to prevent equinus contractures, followed by a nonweight-bearing status for 12 weeks. No studies have been done to validate either end of the spectrum.

Complications

The complications of calcaneus fractures can be divided into two groups: operative and nonoperative. Superficial wound edge necrosis is the most frequently observed operative complication [4,15,26,65,81]. This has been seen in up to 14% of cases after the standard extended lateral approach [15,26,46,65,74], and has been as high as 27% with the combined (medial and lateral) approaches [62]. This increased sensitivity to dehiscence is secondary to presence of the watershed zone in this area. Often, the incision closes easily, but subsequently dehisces as late as 4 weeks postoperatively [4,65,74]. If this occurs, motion should be stopped and the wound should be treated with daily whirlpools and saline dressings to allow for secondary closure. The use of vacuum dressing also is useful in this scenario. Although results are anecdotal, it was found to enhance the formation of healthy granulation tissue in the wound by enhancing the oxygenation. With the use of this dressing, the authors have been able to avoid the need for flap coverage, even in the diabetic smoker. If this is still unsuccessful, a fasciocutaneous flap may be needed [46,82]. The incidence of deep infection is far less common—1.3% to 7% [15,26,47,74]. Most patients do not have diffuse osteomyelitis, but the superficial type, as a result of direct extension from an adjacent source [4]. In this type, the hardware may be retained, but the wound bed should be cleaned thoroughly. The patient should be placed on 6 weeks of intravenous antibiotics. If the osteomyelitis is diffuse, hardware removal is necessary with adequate debridement of bone [4,15,74]. Open fractures, smoking, delay in surgery more than 14 days, and obesity are risk factors for deep infections [4,65,83]. Injuries to the cutaneous nerves frequently affect the sural nerve because of the popularity of the lateral approach [4,74,84]. Medially, the calcaneal branch of the posterior tibial nerve is affected most often [4]. Numbness of the area is mostly observed which is treated nonoperatively. A painful neuroma can develop which should be excised with burial of the stump in deep tissue [4]. Peroneal tendonitis may occur secondary to prominent hardware, or disruption of the tendon sheath and scarring. With the former Kocher approach, the tendon sheaths were violated and the tendons were dislocated to gain better access to the subtalar joint. With the extended lateral approach, a subperiosteal dissection is advocated so as not to disturb the peroneal tendon bed, but rather, elevate them as a whole [59]. If scarring has occurred, an operative release with hardware removal is recommended [4]. As with any surgery, a failed attempt to reduce the joint can lead to arthrosis secondary to incongruity from a malunion. This ability to obtain an adequate reduction is dependent on the

surgeon and on the fracture type. The incidence of nonunion is rare after stable internal fixation. Bone graft and the use of larger screws can aid in healing [15].

Many surgeons treat calcaneus fractures conservatively, either because of lack of familiarity with operative techniques or because they fear the surgical complications; however, complications from nonoperative treatment can be just as troubling. Malunions can be responsible for painful subtalar arthritis, malposition of the talus which leads to tibiotalar impingement and ankle pain, shortening or widening of the hindfoot, fibulocalcaneal impingement, varus or valgus malalignment, impingement or subluxation of the peroneal tendons, or sural or posterior tibial neuritis [3,7,8,20,56,85–87]. Although painful subtalar joint arthritis

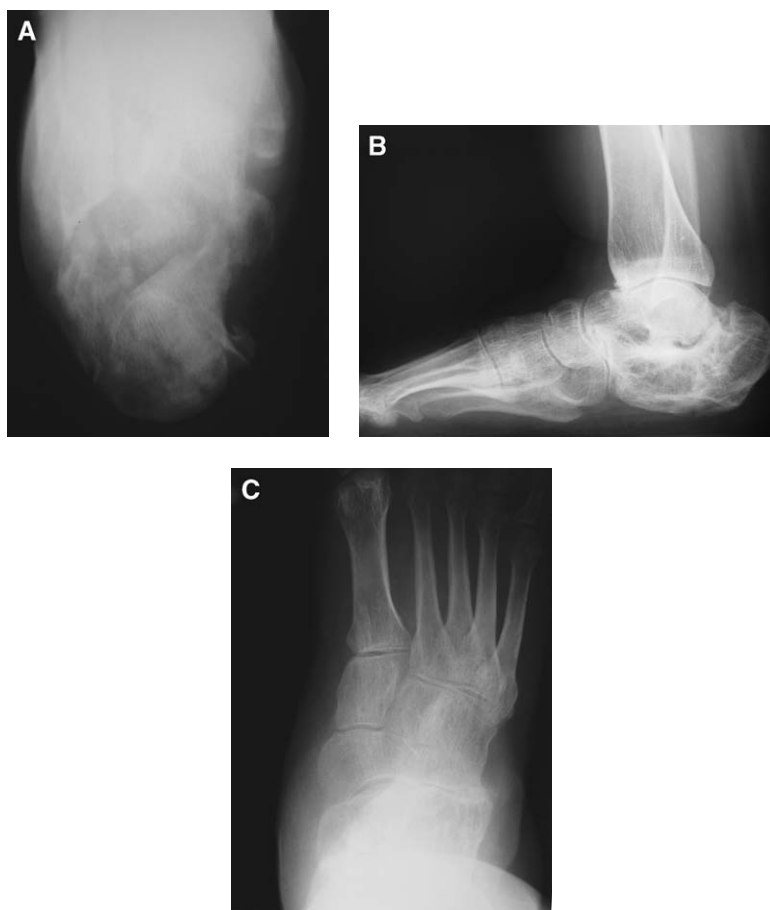


Fig. 12. (A) A Harris view of a calcaneus fracture malunion in varus. The wide heel from the lateral wall blowout and the varus tuberosity cause significant morbidity. (B) A hindfoot lateral view showing significant loss of height and reduction of Böhler's angle, and an increase in the angle of Gissane. No significant subtalar arthrosis is seen. (C) An AP view showing decreased joint space in the calcaneocuboid joint.

can be treated with an isolated subtalar fusion [20], the deformity of the calcaneus must be corrected to restore adequate function to the hindfoot (Fig. 12).

As early as 1921, Cotton [81] noted the maladies that were associated with malunions and recommended decompression of the lateral wall and the lateral aspect of the joint to relieve abutment. Carr et al [88] were the first to suggest subtalar distraction bone block arthrodesis to re-establish calcaneal height and relieve tibiotalar impingement. Romash [89] suggested adding a corrective osteotomy along the former fracture line and reported favorable results in 90% of cases. Stephens and Sanders [86] derived a prognostic classification system for malunions. Type I include a large lateral exostosis with or without extremely lateral subtalar arthrosis. Type II include a calcaneus with a lateral exostosis, combined with arthrosis across the width of the subtalar joint, and type III has a lateral exostosis with severe arthrosis of the subtalar joint and malalignment of the heel in varus or valgus. Treatment is tailored to the type of deformity: lateral wall decompression, peroneal tenolysis, and an extremely lateral joint resection for type I; additional in situ subtalar arthrodesis for type II; and an additional calcaneal osteotomy to correct height and varus/valgus malalignment for type III.

Results of operative treatment

Many clinical studies deal specifically with operative treatments of intra-articular calcaneus fractures. It is still difficult to draw conclusions because many variables exist between them, such as different classification systems, functional outcome measurements, and overall relative low patient numbers [4,13,15]. Five large (>100 patients) studies of intra-articular fractures that were classified by way of CT scanning and treated with ORIF showed good to excellent results in 60% to 85% of cases [5,6,14,59,63]. These studies, however, used different outcome measurements. Sanders et al [6] concluded in their study on 120 calcaneal fractures that: (1) an anatomic articular reduction is needed to obtain an excellent or good result; (2) an anatomic articular reduction cannot ensure a good to excellent result, most likely because of the cartilaginous damage that is incurred at the time of injury; (3) a reproducible operative technique is surgeon dependent and 35 to 50 cases are required to pass the learning curve; and (4) Sanders type IV fractures are so severe that primary arthrodesis is warranted.

Several studies compared nonoperative treatments with operative treatments for displaced intra-articular fractures of more than 2 mm [13,25,49,50,80]. Most of these are retrospective. Although some show significantly greater functional results with ORIF [10,24,25,49,60], others observed no significant difference between the groups [13,50,80]. Two studies [50,80] that showed no significance between operative and nonoperative treatments did show that in patients who were treated operatively, anatomic reduction of the intra-articular surface corresponded with a better clinical score than no reduction or a "less than adequate reduction." The numbers of patients in these studies were not large. One prospective, randomized trial that was evaluated by Thordarson and Krieger [25]

looked at 15 operative cases and 11 nonoperative cases at an average of 17 and 14 months follow-up, respectively. All fractures were Sanders types II and III. They showed 12 good to excellent results in the operative group versus 4 in the nonoperative group. Another larger prospective, randomized, controlled multicenter trial by Buckley et al [13], which involved 471 displaced intra-articular calcaneal fractures, showed that without stratification of the groups, the functional results between operative and nonoperative care were insignificant. When the data were stratified, and when those who were receiving Workman's Compensation benefits were removed from the study, the outcomes were better in the group that was treated operatively. These results also were obtained from many different surgeons. Sanders' classification system was used to stratify the fractures; it was confirmed that those who had less comminution (type II) were three times more likely to score above the mean on the Short Form-36 and Visual Analog Scale when treated operatively. There was no difference between operative and nonoperative treatment in patients who had more comminution (type IV). Postoperatively, Bohler's angle was found to be prognostic. It also was noted that significantly less subtalar fusions were necessary after operative treatment. Among patients who were not receiving Workman's Compensation benefits, women, in general; younger patients (<29 years old); and patients who had a moderately lower Bohler angle, an anatomic reduction, or step off of less than 2 mm scored much higher when treated surgically.

Summary

Calcaneus fractures are a significant burden to society. Assessment and treatment of these injuries has improved significantly over the past 2 decades with the use of CT scanning. It has allowed us greater understanding of the pathologic anatomy of these fractures, and has provided us with a prognostic classification system with respect to outcome. Nonoperative treatment is effective for fractures that are nondisplaced or minimally displaced (<2 mm). ORIF is the standard therapy for fractures that are displaced greater than 2 mm, with 65% to 80% good to excellent results. To obtain these results, the soft tissues always must be respected. Compartment syndrome always should be ruled out clinically and open fractures should be treated aggressively. A minimally invasive approach with the assistance of subtalar arthroscopy is an attractive option for fracture types with minimal comminution (Sanders type II), but should be reserved for the more experienced surgeon. An extended lateral approach respects the local anatomy and provides the best opportunity to restore the congruity of the joint surface. Anatomic restoration of the articular surface and restoration of the original shape of the calcaneus (Bohler's angle) are of prognostic value. These measures can be assessed intraoperatively with the Harris axial view, the lateral hindfoot view, and the Brodén view with fluoroscopy. Patients who have severely comminuted fractures (Sanders type IV) can be treated with an ORIF of the body of the calcaneus combined with primary subtalar arthrodesis.

References

- [1] Crosby LA, Fitzgibbons T. Computerized tomography scanning of acute intra-articular fractures of the calcaneus. A new classification system. *J Bone Joint Surg Am* 1990;72:852–9.
- [2] Essex-Lopresti P. The mechanism, reduction technique, and results in fractures of the os calcis. *Br J Surg* 1952;39:395–419.
- [3] Sanders R. Intra-articular fractures of the calcaneus: present state of the art. *J Orthop Trauma* 1992;6:252–65.
- [4] Sanders R. Displaced intra-articular fractures of the calcaneus. *J Bone Joint Surg Am* 2000;82:225–50.
- [5] Zwipp H, Tscherne H, Thermann H, et al. Osteosynthesis of displaced intra-articular fractures of the calcaneus. Results in 123 cases. *Clin Orthop* 1993;290:76–86.
- [6] Sanders R, Fortin P, DiPasquale A, et al. Operative treatment in 120 displaced intra-articular calcaneal fractures. Results using a prognostic computed tomographic scan classification. *Clin Orthop* 1993;290:87–95.
- [7] Carr JB, Hansen S, Benirschke S. Subtalar distraction bone block fusion for late complications of os calcis fractures. *Foot Ankle* 1988;9:81–6.
- [8] James ET, Hunter GA. The dilemma of painful old os calcis fractures. *Clin Orthop* 1983;177:112–5.
- [9] Myerson M, Quill G. Late complications of fractures of the calcaneus. *J Bone Joint Surg Am* 1993;75:331–41.
- [10] Catani F, Benedetti MG, Simoncini L. Analysis of function after intra-articular fracture of the os calcis. *Foot Ankle Int* 1999;20:417–21.
- [11] Sangeorzan B. Salvage procedures for calcaneus fractures. *Instr Course Lect* 1997;46:339–46.
- [12] Böhler L. Diagnosis, pathology, and treatment of fractures of the os calcis. *J Bone Joint Surg* 1931;13:75–89.
- [13] Buckley R, Tough S, McCormack R. Operative compared with nonoperative treatment of displaced intra-articular fractures: a prospective, randomized, controlled multicenter trial. *J Bone Joint Surg Am* 2002;84:1733–44.
- [14] Conn HR. The treatment of fractures of the os calcis. *J Bone Joint Surg* 1935;17:392–405.
- [15] Rammelt S, Zwipp H. Calcaneus fractures: facts, controversies and recent developments. *Injury* 2004;35:443–61.
- [16] Cotton FJ, Henderson FF. Results of fractures of the os calcis. *Am J Orthop Surg* 1916;14:290–8.
- [17] Carr JB, Hamilton JJ, Bear LS. Experimental intra-articular calcaneal fractures: anatomical basis for a new classification. *Foot Ankle* 1989;10:81–7.
- [18] Cotton FJ, Wilson LT. Fractures of the os calcis. *Boston Med J* 1908;159:559–65.
- [19] McLaughlin HL. Treatment of complications after os calcis fractures. *Clin Orthop* 1963;30:111–5.
- [20] Gallie WE. Subastragalar arthrodesis in fractures of the os calcis. *J Bone Joint Surg* 1943;25:731–6.
- [21] Palmer I. The mechanism and treatment of fractures of the calcaneus. *J Bone Joint Surg Am* 1948;30:2–8.
- [22] Lindsay WRN, Dewar FP. Fractures of the os calcis. *Am J Surg* 1958;95:555–76.
- [23] Rowe CR, Sakellarides HT, Freeman PA, et al. Fractures of os calcis. A long term follow-up study of one hundred forty-six patients. *JAMA* 1963;184:920–3.
- [24] Crosby LA, Fitzgibbons TC. Open reduction and internal fixation of type II intra-articular calcaneus fractures. *Foot Ankle Int* 1996;17:253–8.
- [25] Thordarson DB, Krieger LE. Operative vs. nonoperative treatment of intra-articular fractures of the calcaneus: a prospective randomized trial. *Foot Ankle Int* 1996;17:2–9.
- [26] Benirschke SK, Sangeorzan BJ, Hansen ST. Results of operative treatment of calcaneal fractures of the foot. Surgical management of calcaneal fractures. *Clin Orthop* 1993;292:128–34.
- [27] Hall RL, Shereff MJ. Anatomy of the calcaneus. *Clin Orthop* 1993;290:27–35.
- [28] Sarrafian SK. Anatomy of the foot and ankle. Philadelphia: Lippincott; 1993.

- [29] Sabry FF, Ebraheim NA, Mehalik JN, et al. Internal architecture of the calcaneus: implications for calcaneus fractures. *Foot Ankle Int* 2000;21:114–8.
- [30] Soeur R, Remy R. Fractures of the calcaneus with displacement of the thalamic portion. *J Bone Joint Surg Br* 1975;57:413–21.
- [31] Harty M. Anatomic consideration in injuries of the calcaneus. *Orthop Clin North Am* 1973;4:179–83.
- [32] Carr JB. Mechanism and pathoanatomy of the intra-articular calcaneal fracture. *Clin Orthop* 1993;290:36–40.
- [33] Burdeaux BD. Reduction of calcaneal fractures by the McReynolds medial approach technique and its experimental basis. *Clin Orthop* 1983;177:87–103.
- [34] Wülker N, Zwipp H. Fracture anatomy of the calcaneus with axial loading. *Foot Ankle Surg* 1986;2:155–62.
- [35] Koval KJ, Sanders R. The radiologic evaluation of calcaneal fractures. *Clin Orthop* 1993;290:41–6.
- [36] Gissane W. News notes: Proceedings of the British Orthopedic Association. *J Bone Joint Surg* 1947;29:254–5.
- [37] Brodén B. Roentgen examination of the subtaloid joint in fractures of the calcaneus. *Acta Radiol* 1949;31:85–91.
- [38] Janzen DL, Connell DG, Munk PL, et al. Intraarticular fractures of the calcaneus: value of CT findings in determining prognosis. *American Journal of Roentgenology* 1992;158:1271–4.
- [39] Prasarthitha T, Sethavanitch C. Three-dimensional and two-dimensional computerized tomographic demonstration of calcaneus fractures. *Foot Ankle Int* 2004;25:262–73.
- [40] Hansen Jr S. *Foot injuries*. In: *Skeletal trauma*. 2nd edition. Philadelphia: W.B Saunders Company; 1998. p. 2405–38.
- [41] Giordano CP, Koval KJ, Zuckerman JD, et al. Fracture blisters. *Clin Orthop* 1994;307:214–21.
- [42] Giordano CP, Koval KJ. Treatment of fracture blisters: a prospective study of 53 cases. *J Orthop Trauma* 1995;9:171–6.
- [43] Manoli AD, Weber TG. Fasciotomy of the foot: an anatomical study with special reference to release of the calcaneal compartment. *Foot Ankle* 1990;10:267–75.
- [44] Myerson M, Manoli A. Compartment syndromes of the foot after calcaneal fractures. *Clin Orthop* 1993;290:142–50.
- [45] Baumgaertel FR, Gotzen L. Two stage operative treatment of comminuted os calcis fractures: primary indirect reduction with medial external fixation and delayed lateral plate fixation. *Clin Orthop* 1993;290:132–41.
- [46] Bezes H, Massart P, Delvaux D, et al. The operative treatment of intraarticular calcaneal fractures. Indications, technique, and results in 257 cases. *Clin Orthop* 1993;290:55–9.
- [47] Brenner P, Rammelt S, Gavlik JM, et al. Early soft tissue coverage after complex foot trauma. *World J Surg* 2001;25:603–9.
- [48] Torretta III P. The Essex-Lopresti reduction for calcaneal fractures revisited. *J Orthop Trauma* 1998;12:469–73.
- [49] Randle JA, Kreder HJ, Stephen D, et al. Should calcaneal fractures be treated surgically? *Clin Orthop* 2000;377:217–27.
- [50] Buckley RE, Meek RN. Comparison of open versus closed reduction of intraarticular calcaneal fractures: a matched cohort in workmen. *J Orthop Trauma* 1992;6:216–22.
- [51] Rammelt S, Gavlik JM, Barthel S, et al. The value of subtalar arthroscopy in the management of intra-articular calcaneus fractures. *Foot Ankle Int* 2002;23:906–16.
- [52] Gavlik JM, Rammelt S, Zwipp H. Percutaneous, arthroscopically-assisted osteosynthesis of calcaneus fractures. *Arch Orthop Trauma Surg* 2002;122:424–8.
- [53] Gavlik JM, Rammelt S, Zwipp H. The use of subtalar arthroscopy in open reduction and internal fixation of intra-articular calcaneal fractures. *Injury* 2002;33:63–71.
- [54] Mulcahy DM, McCormack DM, Stephens MM. Intra-articular calcaneal fractures: effect of open reduction and internal fixation on the contact characteristics of the subtalar joint. *Foot Ankle Int* 1998;19:842–8.

- [55] Sangeorzan BJ, Ananthkrishnan D, Tencer AF. Contact characteristics of the subtalar joint after a simulated calcaneus fracture. *J Orthop Trauma* 1995;9:251–8.
- [56] Crosby LA, Fitzgibbons TC. Intra-articular calcaneal fractures. Results of closed treatment. *Clin Orthop* 1993;290:47–54.
- [57] Burdeaux BD. Fractures of the calcaneus: open reduction and internal fixation from the medial side, a 21-year prospective study. *Foot Ankle Int* 1997;18:685–92.
- [58] Laughlin RT, Carson JG, Calhoun JH. Displaced intra-articular calcaneus fractures treated with the Galveston plate. *Foot Ankle Int* 1996;17:71–8.
- [59] Letournel E. Open reduction and internal fixation of calcaneal fractures. *Clin Orthop* 1993;290:60–7.
- [60] Leung KS, Yuen KM, Chan WS. Operative treatment of displaced intra-articular fractures of the calcaneum. Medium-term results. *J Bone Joint Surg Br* 1993;75:196–201.
- [61] Paley D, Hall H. Intra-articular fractures of the calcaneus. A critical analysis of results and prognostic factors. *J Bone Joint Surg Am* 1993;75:342–54.
- [62] Stephenson JR. Treatment of displaced intra-articular fractures of the calcaneus using medial and lateral approaches, internal fixation, and early motion. *J Bone Joint Surg Am* 1987;69:115–30.
- [63] Thordarson DB, Latteier M. Open reduction and internal fixation of calcaneal fractures with a low profile titanium calcaneal perimeter plate. *Foot Ankle Int* 2003;24:217–21.
- [64] Omoto H, Nakamura K. Method for manual reduction of displaced intra-articular fracture of the calcaneus: technique, indications and limitations. *Foot Ankle Int* 2001;22:874–9.
- [65] Abidi NA, Dhawan S, Gruen GS, et al. Wound healing risk factors after open reduction and internal fixation of calcaneal fractures. *Foot Ankle Int* 1998;19:856–61.
- [66] Burton DC, Olney BW, Horton GA. Late results of subtalar distraction fusion. *Foot Ankle Int* 1998;19:197–202.
- [67] Chandler JT, Bonar SK, Anderson RB, et al. Results of in situ subtalar arthrodesis for late sequelae of calcaneus fractures. *Foot Ankle Int* 1999;20:18–24.
- [68] Folk JW, Star AJ, Early JS. Early wound complications of operative treatment of calcaneus fractures: analysis of 190 fractures. *J Orthop Trauma* 1999;13:369–72.
- [69] Gardner AM, Fox RH, Lawrence C, et al. Reduction of post-traumatic swelling and compartment pressure by impulse compression of the foot. *J Bone Joint Surg Br* 1990;72:810–5.
- [70] Myerson MS, Henderson MR. Clinical application of a pneumatic intermittent impulse compression device after trauma and major surgery to the foot and ankle. *Foot Ankle Int* 1996;14:198–203.
- [71] Ebraheim NA, Elgafy H, Sabry FF, et al. Sinus tarsi approach with trans-articular fixation for displaced intra-articular fractures of the calcaneus. *Foot Ankle Int* 2000;21:105–13.
- [72] Stephenson JR. Surgical treatment of displaced intraarticular fractures of the calcaneus: a combined lateral and medial approach. *Clin Orthop* 1993;290:68–75.
- [73] Gould N. Lateral approach to the os calcis. *Foot Ankle* 1984;4:218–20.
- [74] Harvey EJ, Grujic L, Early JS, et al. Morbidity associated with ORIF of intra-articular calcaneus fractures using the lateral approach. *Foot Ankle Int* 2001;22(11):868–73.
- [75] Stephenson JR. Displaced fractures of the os calcis involving the subtalar joint: the key role of the superomedial fragment. *Foot Ankle* 1983;4:91–101.
- [76] Longino D, Buckley RE. Bone graft in the operative treatment of displaced intra-articular calcaneal fractures: is it helpful. *J Orthop Trauma* 2001;15:280–6.
- [77] O'Farrell D, Jim OB, McCabe JP, et al. Fractures of the os calcis: improved results with internal fixation. *Injury* 1993;24:263–5.
- [78] Tile M. Fractures of the calcaneus. In: Schatzker J, Tile M, editors. *The rationale of operative fracture care*. Berlin: Springer-Verlag; 1996. p. 589–603.
- [79] Buch BD, Myerson MS, Miller SD. Primary subtalar arthrodesis for the treatment of comminuted calcaneal fractures. *Foot Ankle Int* 1996;17:61–70.
- [80] Kundel K, Funk E, Brutscher M, et al. Calcaneal fractures: operative versus nonoperative treatment. *J Trauma* 1996;41:839–45.
- [81] Levin LS, Nunley JA. The management of soft-tissue problems associated with calcaneal fractures. *Clin Orthop* 1993;290:151–6.

- [82] Brenner P, Rammelt S, Gavlik JM, et al. Early soft tissue coverage after complex foot trauma. *World J Surg* 2001;25:603–9.
- [83] Attinger C, Cooper B. Soft tissue reconstruction for calcaneal fractures or osteomyelitis. *Orthop Clin North Am* 2001;32:135–70.
- [84] Paley D, Hall H. Intra-articular fractures of the calcaneus. A critical analysis of results and prognostic factors. *J Bone Joint Surg Am* 1993;75:342–54.
- [85] Kitaoka HB, Schaap EJ, Chao EY, et al. Displaced intra-articular fractures of the calcaneus treated non-operatively. Clinical results and analysis of motion and ground-reaction and temporal forces. *J Bone Joint Surg Am* 1994;76:1531–40.
- [86] Stephens HM, Sanders R. Calcaneal malunions: results of a prognostic computed tomography classification system. *Foot Ankle Int* 1996;17:395–401.
- [87] Cotton FJ. Old os calcis fractures. *Ann Surg* 1921;74:294–303.
- [88] Carr JB, Hansen S, Benirschke S. Subtalar distraction bone block fusion for late complications of os calcis fractures. *Foot Ankle* 1988;9:81–6.
- [89] Romash MM. Reconstructive osteotomy of the calcaneus with subtalar arthrodesis for malunited calcaneal fractures. *Clin Orthop* 1993;290:157–67.